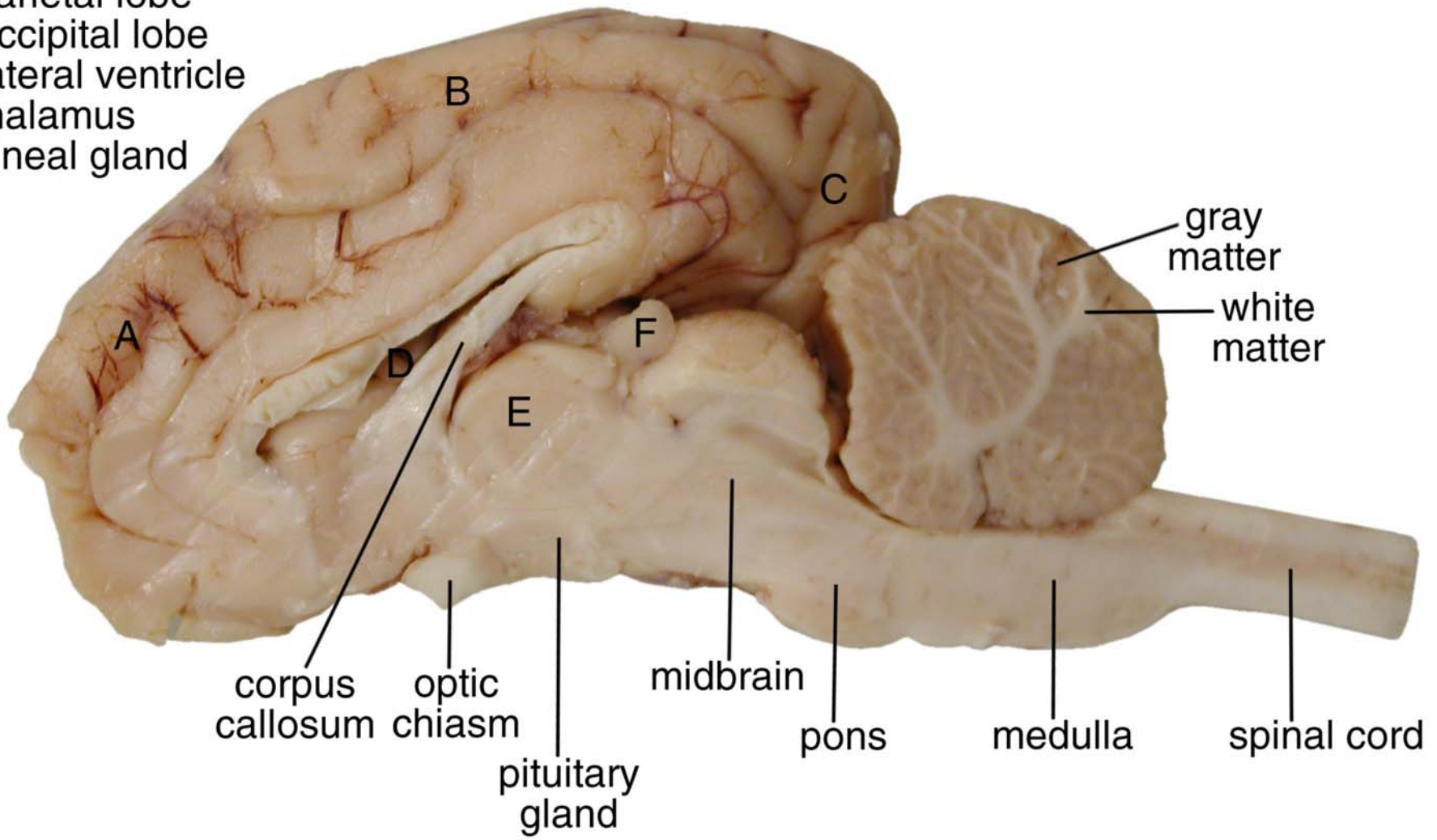


- A. frontal lobe
- B. parietal lobe
- C. occipital lobe
- D. lateral ventricle
- E. thalamus
- F. pineal gland



- gray matter
- white matter
- corpus callosum
- optic chiasm
- pituitary gland
- midbrain
- pons
- medulla
- spinal cord